

Pitfalls in deformation imaging

Asbjørn Støylen,
Dr. Med.
NTNU

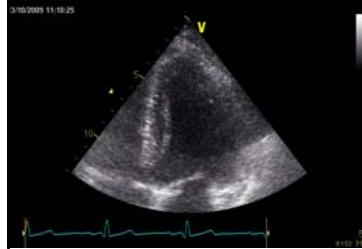
<http://folk.ntnu.no/stoylen/strainrate/>
<http://folk.ntnu.no/stoylen/strainrate/Howto/Pitfalls.html>

NTNU

1

ST. OLAVS HOSPITAL

Left ventricular function:



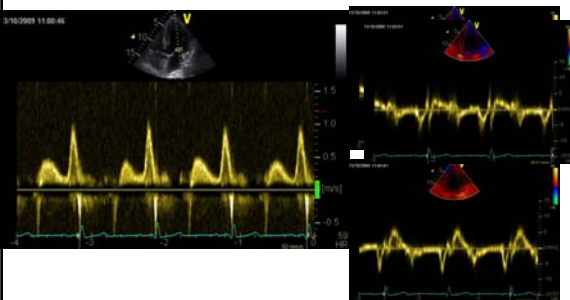- No dyspnea
- EF = 60%

NTNU

2

ST. OLAVS HOSPITAL

Left ventricular function

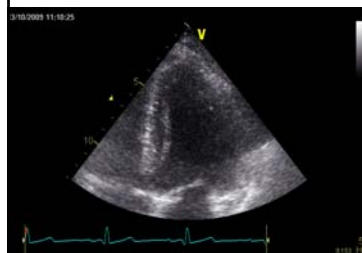

NTNU

3

ST. OLAVS HOSPITAL

Left ventricular function:



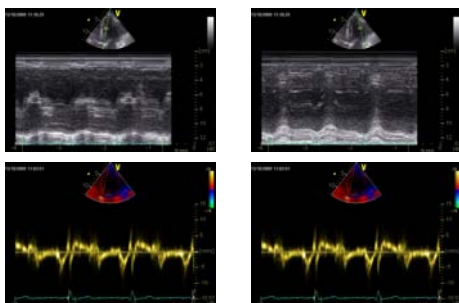
- No dyspnea
- EF = 60%
- EDV = 74 ml
- ESV = 32 ml
- SV 42 ml
- CO 2.4 l/min
- Main symptom: Fatigue

NTNU

4

ST. OLAVS HOSPITAL

Left ventricular function:



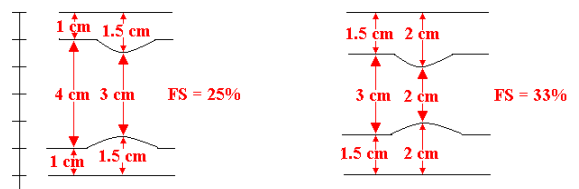
Annular displacement 7 mm, S' 4.5 cm/s

NTNU

5

ST. OLAVS HOSPITAL

Left ventricular function:

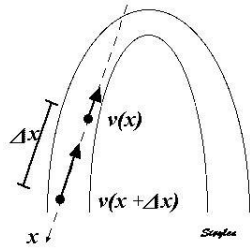


NTNU

6

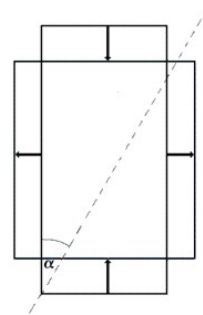
ST. OLAVS HOSPITAL

Strain rate:

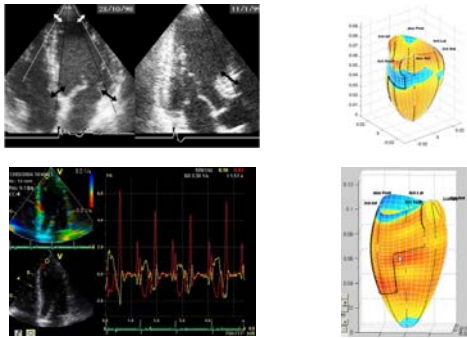


$$SR = \frac{v(x) - v(x + \Delta x)}{\Delta x}$$

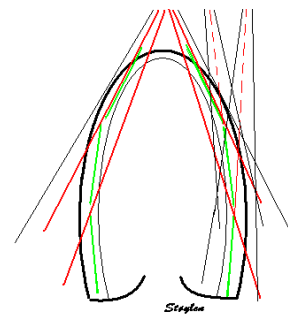
The angle problem:



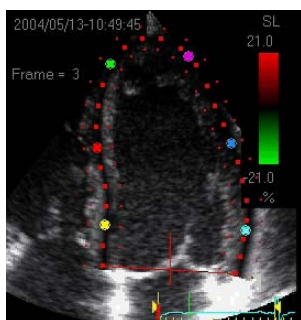
The angle problem:



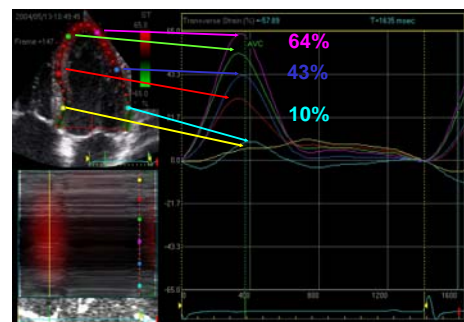
Alignment with the wall:



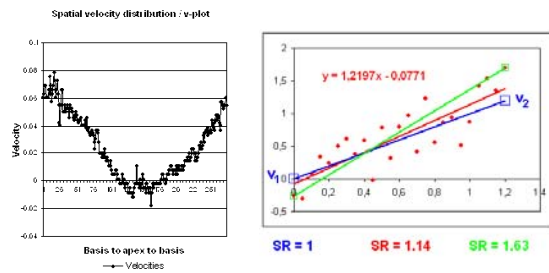
Angle dependency of speckle tracking



Lateral resolution – transmural strain:

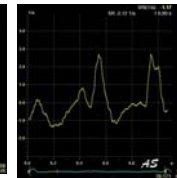
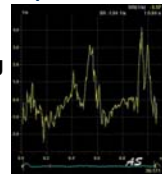


Random noise:



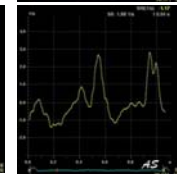
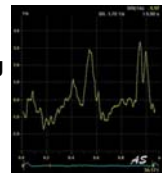
Temporal smoothing (Frame rate 185, offset 4 mm)

No smoothing



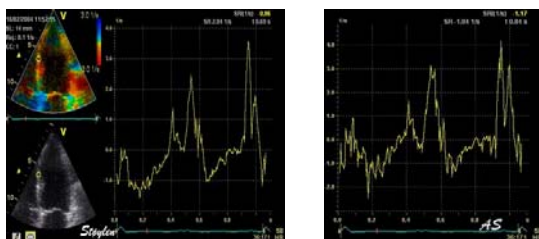
Flat smoothing
7 samples
= 35 ms

Gaussian smoothing
40 ms



Gaussian smoothing
80 ms

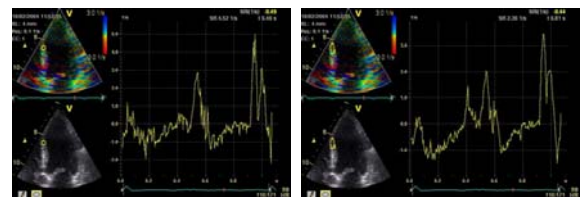
Strain length- improved signal / noise ratio



Offset 14 mm 4 mm

Increased offset: Larger difference between $v(x)$ and $v(\Delta x)$
– reduced axial resolution

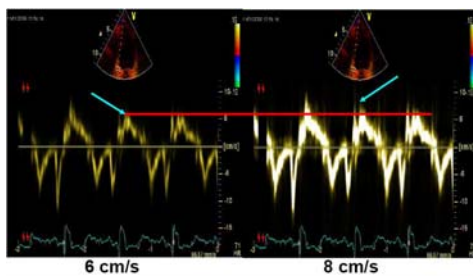
Spatial averaging



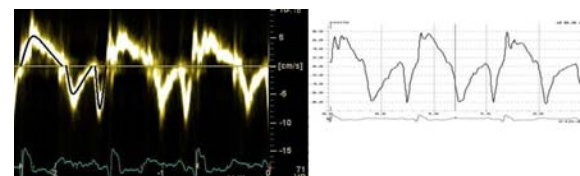
Offset 4 mm, no temporal smoothing

ROI 6x6 mm ROI 12x6 mm

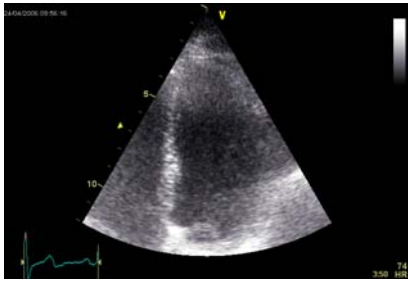
Velocities



Velocities



Velocities

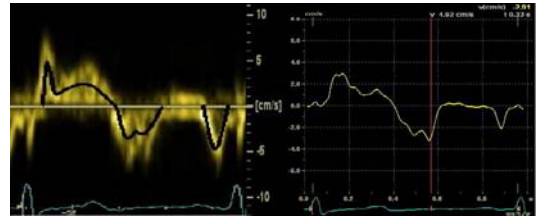


NTNU

19

ST. OLAVS HOSPITAL

Velocities

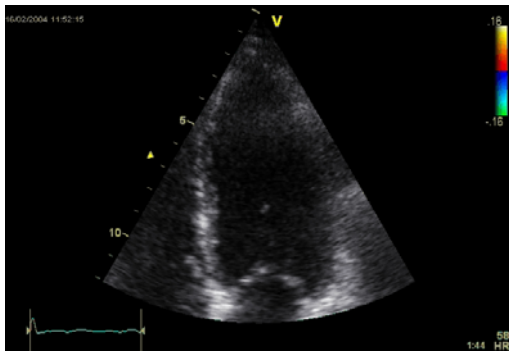


NTNU

20

ST. OLAVS HOSPITAL

Reverberations:



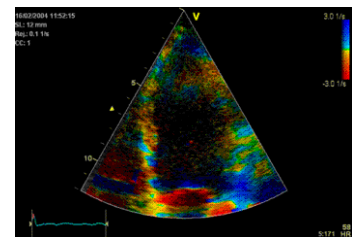
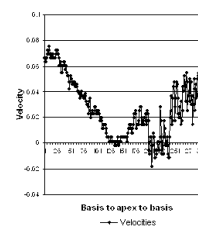
NTNU

21

ST. OLAVS HOSPITAL

Reverberations:

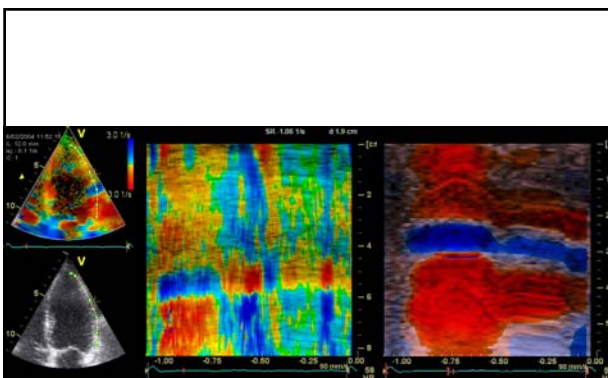
Spatial velocity distribution : v-plot



NTNU

22

ST. OLAVS HOSPITAL

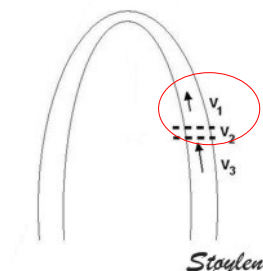
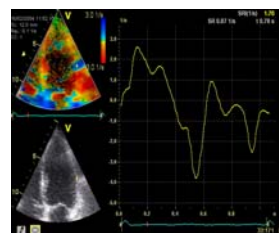


NTNU

23

ST. OLAVS HOSPITAL

Reverberation artefact:



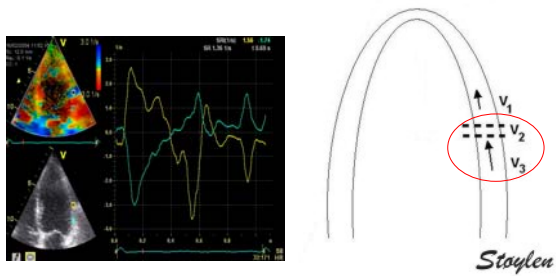
Apparent dyskinesia

NTNU

24

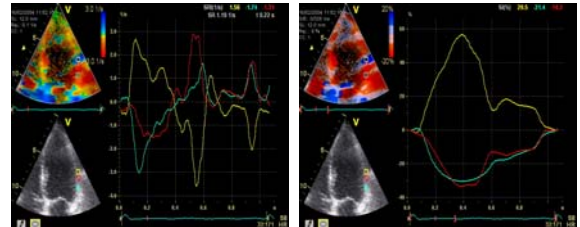
ST. OLAVS HOSPITAL

Reverberation artefact:



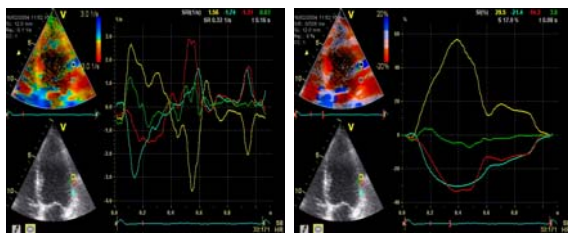
Apparent hyperkinesia

Reverberation artefact:



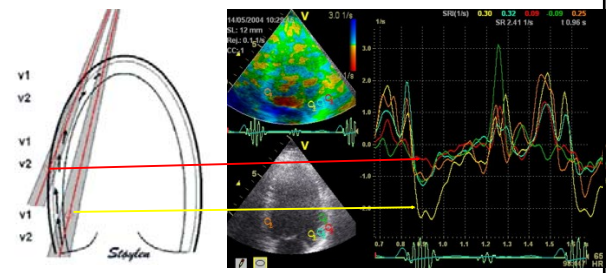
Apparent normal strain rate

Reverberation artefact:



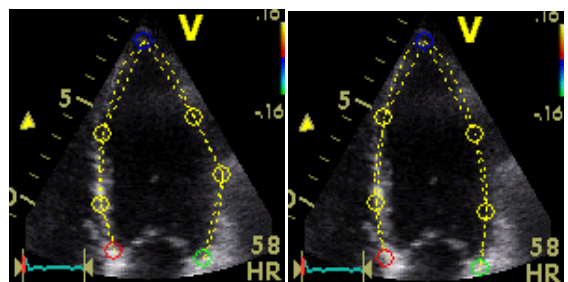
Apparent initial dyskinesia

Lateral resolution:

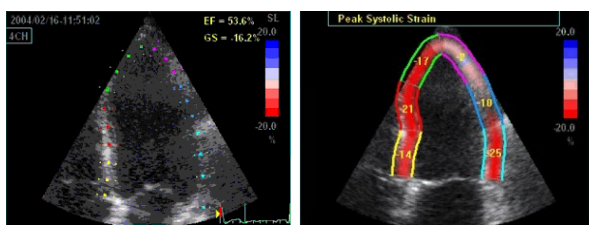


$$SR = \frac{v1 - v2}{L}$$

Reverberation artefact:

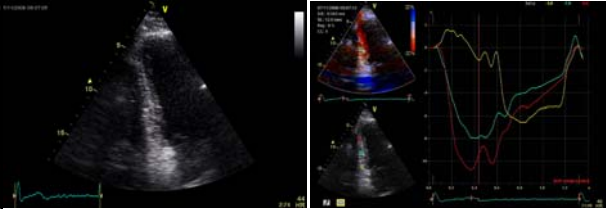


Smoothing:



The smoothing gives an interdependence of measurements

Inferior infarct:



Inferior infarct:

