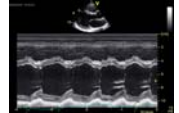


M-mode og B-mode ekkokardiografi

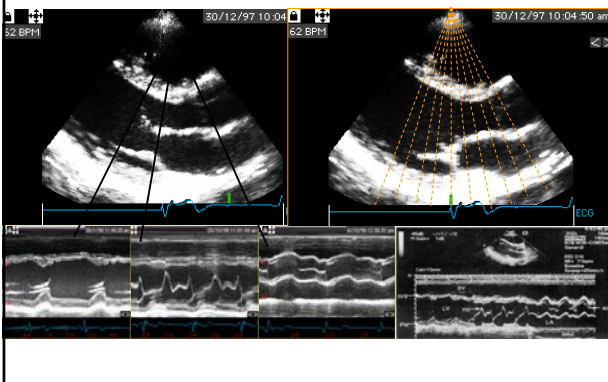
Håvard Dalen
Klinikk for hjertemedisin, St Olav
NTNU

M-mode

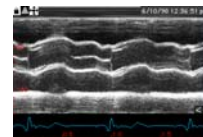
- I bruk før todimensjonal ekkokardiografi
- Høy pulsrepetisjonsfrekvens gir meget god tidsopløsning
- Standardisert gir M-mode god reproduserbarhet av målinger
- "Leading edge"-prinsippet



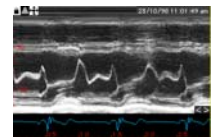
M-modelinjer:



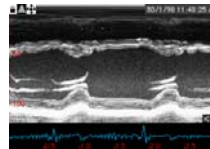
M-mode ekkokardiografi:



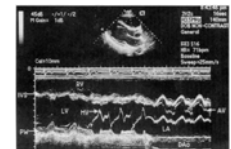
Aorta



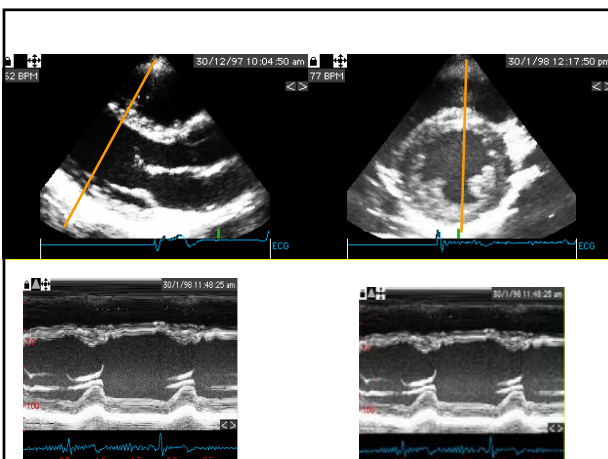
Mitral



Ve. ventrikel



Sweep

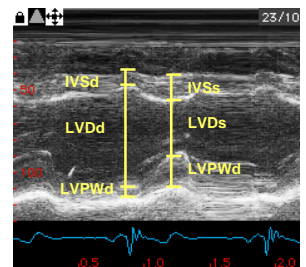


Kortakse M-mode:

Diastolisk: Start av QRS

Systolisk: Septums mest posteriore punkt

NB! Chordae i HV
NB! Mål mellom mitral-
klaff og papillemuskel



- Diameter og forkortningsfraksjon (FF eller SF):

$$FF = (LVD_d - LVD_s) / LVD_d$$

- Veggtykkelse og veggfortykning $WT = (WT_s - WT_d) / WT_d$

Kortakse M-mode:

- **Fordeler:**
 - Enkel i bruk
 - Relativt reproduserbar
 - Både dilatasjon og funksjon
 - Både hypertrofi og funksjon
- **Ulemper:**
 - Mange pasienter har ikke parasternalt vindu
 - Virker ikke der det er regionale forskjeller (infarktsekvele)
 - Langaksefunksjon ofte tidligere nedsatt enn tverrakse

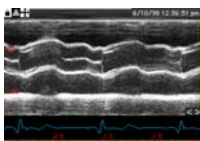
NB: Husk at noen pasienter har et godt subcostalt vindu for M-mode!

Normalverdier:

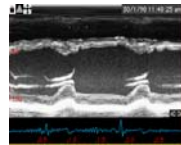
Ekkokardiografisk mål		Kvinner(n=95)	Menn(n=95)
LVEDS cm	cm m-1	2,78±0,33	1,56±0,20
LVEDD cm	cm m-1	4,71±0,41	2,70±0,33
LV-SF		43±5	41±6
IVS ED cm	cm m-1	0,86±0,12	0,50±0,08
LWPW cm	cm m-1	0,84±0,10	0,48±0,05
LA cm	cm m-1	3,14±0,43	1,81±0,25
Aortarot cm	cm	2,72±0,30	1,81±0,25
RV - ED cm	cm	1,72±0,48	1,00±0,28

Knutsen et al 1989

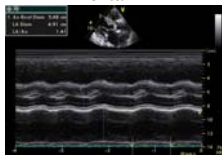
M-mode ekkokardiografi:



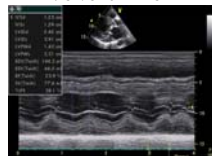
Aorta



Ve ventrikkell

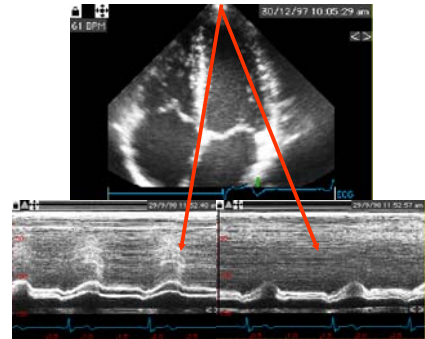


Aortastenose



HOCM

Mitral annulus excursion



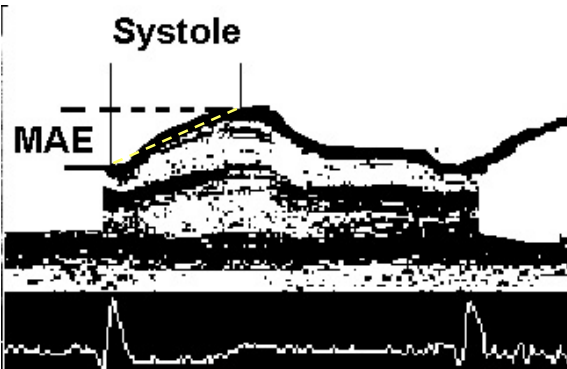
Mitral annulus excursion

- MAE > 10 mm tilsvarer EF > 50%
- MAE < 7 mm Tilsvarer EF < 30%

Alam et al 1992

- Korrelasjon MAE og EF 0,80

Støylen et al 2003



2D-ekko

Todimensjonal ekkokardiografi:

Kartlegging av anatomi

Systematisk undersøkelse for å undersøke alt...

Ulike vinkler

Kompromiss mellom bildeoppdateringshastighet og oppløsning

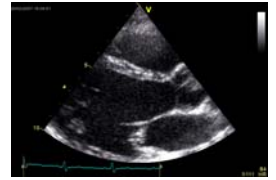
Patologiske funn er sikrere når det gjenfinnes fra ulike vinkler

B-mode

➤ Todimensjonal ekkokardiografi

➤ (Brightness mode)

➤ Levende bilder

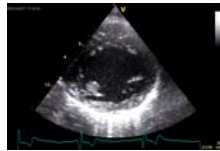


Todimensjonal ekkokardiografi

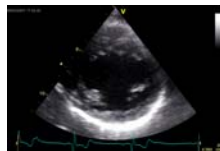
Frame per sek ca 40 - 100

Høyere FPS gir lavere linjetetthet

Ekkokardiografi er hele tiden kompromisser



44 fps



95 fps

Todimensjonal ekkokardiografi

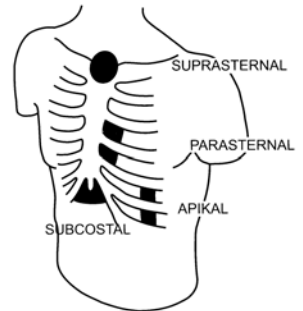
Standardposisjoner

✓ Parasternalt

✓ Apikalt

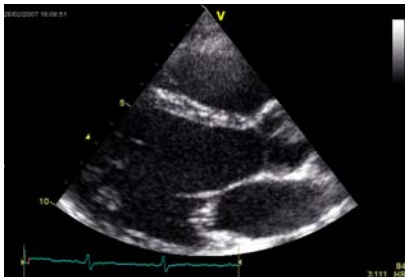
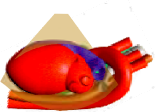
✓ Subcostalt

✓ Suprasternalt



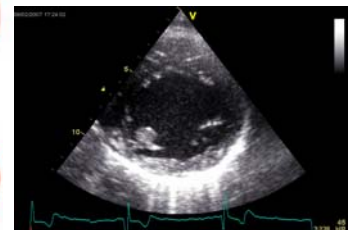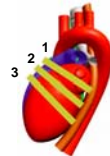
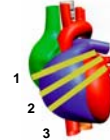Parasternalt vindu

Langakse



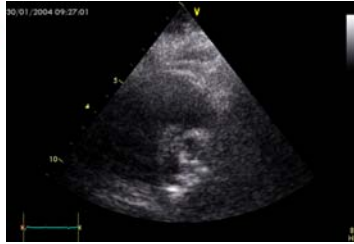
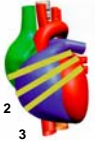Parasternalt vindu

Kortakse



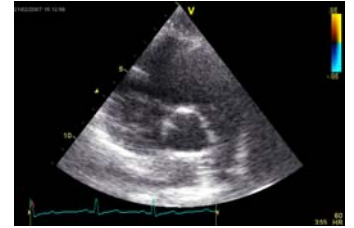
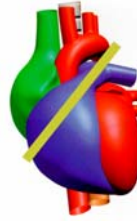Parasternalt vindu

Kortakse
Aortaostiet



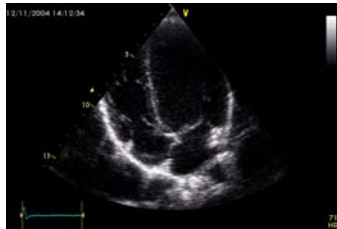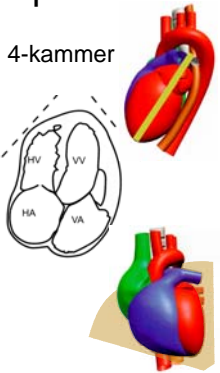
Parasternalt vindu

Kortakse
A pulmonalis



Apikalt vindu

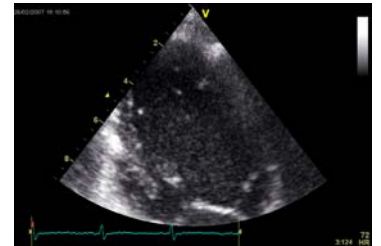
4-kammer



Apikalt vindu

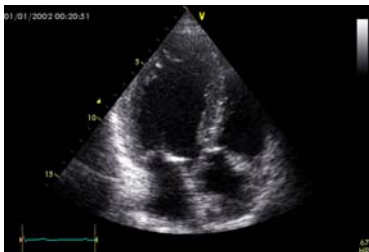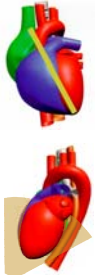
2-kammer

Transducer dreid
ca 60 gr mot
klokka fra
4K-bilde



Apikalt vindu

Langakse

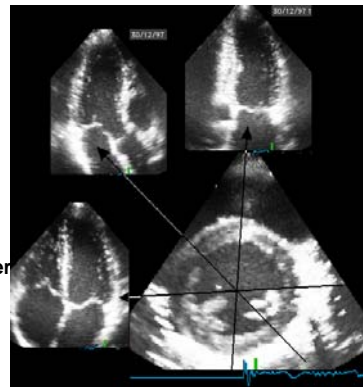


Apical
langakse

Apical
tokammer

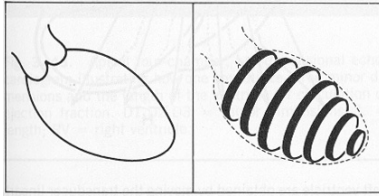
Apical
firekammer

Parasternal
kortakse



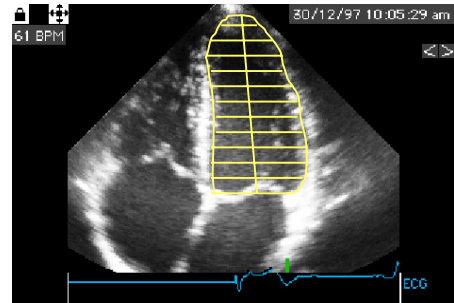
Global funksjon

Simpson's metode



Feigenbaum 4th ed

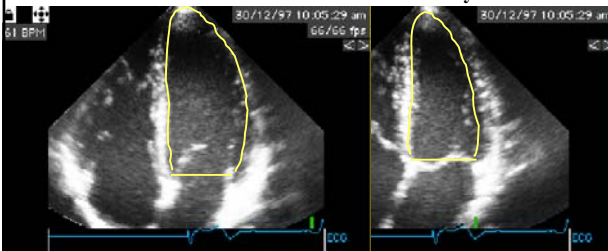
Modifisert Simpson



Ejeksjonsfraksjon

Diastole

Systole



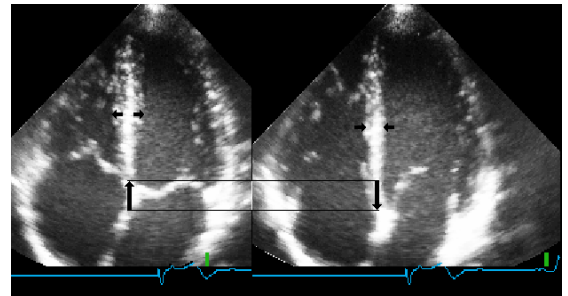
$$SV = EDV - ESV$$

Normalt > 45 ml / m²

$$EF = SV / EDV$$

Normalt > 50%

Langaksebevegelsen



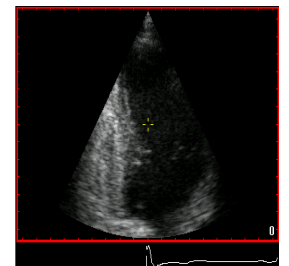
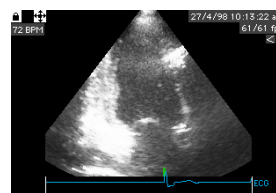
Regional funksjon

2D-ekkokardiografi vellegnet til vurdering av regional funksjon (i motsetning til M-mode)

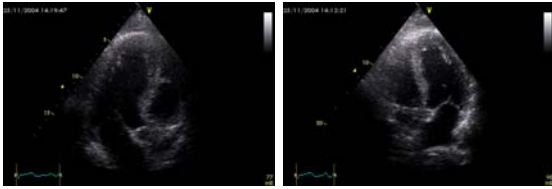
Lokalisasjon av patologi

Segmentinndeling av venstre ventrikel

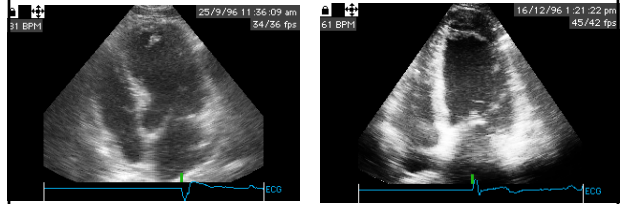
Nedre veggs infarkt



Fremre veggs infarkt



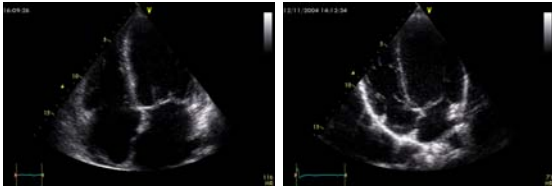
Fremre veggs infarkt med trombe i apex



Eksempler patologi ved 2D-ekko

Dilatert kardiomyopati

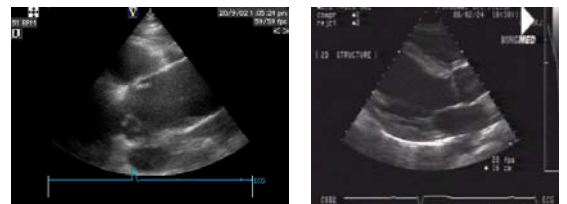
Normalt



Eksempler patologi ved 2D-ekko

A-disseksjon i a. asc.

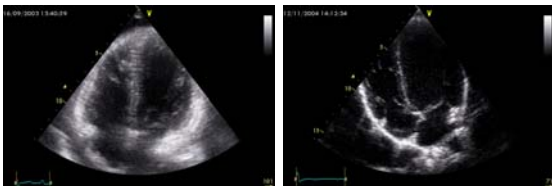
Normalt



Eksempler patologi ved 2D-ekko

Perikardvæske

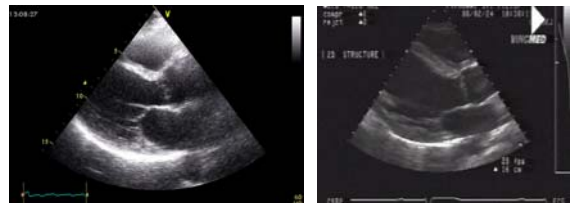Normalt



Eksempler patologi ved 2D-ekko

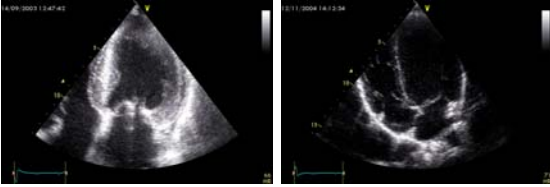
Sekvele FVI

Normalt



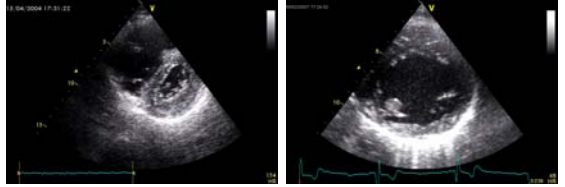Eksempler patologi ved 2D-ekko

Hypertrof kardiomyopati Normalt



Eksempler patologi ved 2D-ekko

Akutt cor pulmonale Normalt



Eksempler patologi ved 2D-ekko

Bicuspid aortaklaff Normal trikuspid klaff

